

## Superior Mesenteric Artery Syndrome: an Uncommon Cause of Duodenal Obstruction.

K M Garg<sup>1</sup>, Neha Gupta<sup>2</sup>, Alok Maheshwari<sup>3</sup>

<sup>1</sup>phod Surgery Jnuimsrsc Jaipur,

<sup>2</sup>senior Resident Anesthesiology Sms Hospital Jaipur,

<sup>3</sup>senior Consultant Surgery Deep Hospital And Research Centre Jaipur

**Abstract:** Superior mesenteric artery (SMA) syndrome is a rare acquired disorder in which acute angulation of SMA causes compression of the third part of the duodenum between the SMA and the aorta, leading to upper gastrointestinal obstruction. Loss of fatty tissue as a result of a variety of debilitating conditions is believed to be the etiologic factor, most frequently occurs in patients who have rapid weight loss. Identification of this syndrome can be a diagnostic dilemma. We report a case of 30 year male who was diagnosed by computed tomogram, patient had a rapid downhill path and underwent operation within 10 days. Duodeno-jejunostomy was done by a Roux-en-Y jejunal loop as an operative treatment. Postoperative three months follow-up was uneventful.

**Keywords:** Arterio – mesenteric duodenal compression syndrome, chronic duodenal ileus, wilkie’s syndrome, Superior mesenteric artery syndrome

### I. Introduction

Vascular compression of the duodenum, also known as superior mesenteric artery syndrome or Willkie’s syndrome, is a rare condition characterized by compression of the third portion of the duodenum by the superior mesenteric artery as it passes over this portion of the duodenum.

Loss of fatty tissue as a result of a variety of debilitating conditions is believed to be the etiologic factor causing acute angulation. Identification of this condition can be a diagnostic dilemma. We report a case of 30 years old male who was diagnosed by computed tomogram, had a rapid downhill path and underwent duodeno-jejunostomy with a fast recovery.

### II. Case Report

A 30 year old male patient presented with six months history of vomiting two to three times weekly and this increased to three to four times daily during the last two weeks before admission. The vomitus consisted of only recently ingested food without any blood. The patient also presented with rapid weight loss ie. about 5 kg in last 1 month. On admission the patient was of thin built and extremely weak with signs of severe dehydration. A nasogastric tube was inserted and the fluid and electrolyte balance was corrected by parenteral infusion of crystalloid fluids with electrolytes. Two days later the patient was subjected to U G I gastro-duodenoscopy which revealed large capacity of stomach containing food material and liquids. Visualized mucosa of stomach was normal. Further duodenum have luminal narrowing with mucosal oedema at D1-D2 junction. Patient’s hemoglobin was 8 gm %, leucocyte count was 12.9 thousands/cmm. Serum albumin was 2 gm /dl. He underwent computed tomogram revealing grossly distended stomach and duodenum up to D3 segment(Fig 1) with narrowed mid transverse duodenal segment between the aorta and SMA. Hence a possibility of SMA syndrome. Patient was advised conservative treatment for which he denied and therefore he was subjected to laparotomy. The first and second parts of duodenum were dilated and hypertrophied, the dilated duodenum was abruptly at the point where the superior mesenteric artery crossed the third part of duodenum. These findings confirmed the diagnosis and a side to end duodeno-jejunostomy by a Roux-en-y jejunal loop was performed (Fig 2). Post operative period was uneventful. Patient was well and even gained weight when last seen at 3 months follow up.

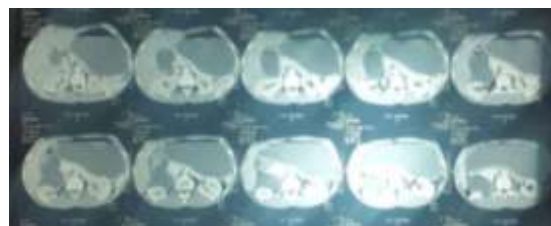


FIG 1 – CECT reveals grossly distended stomach and duodenum

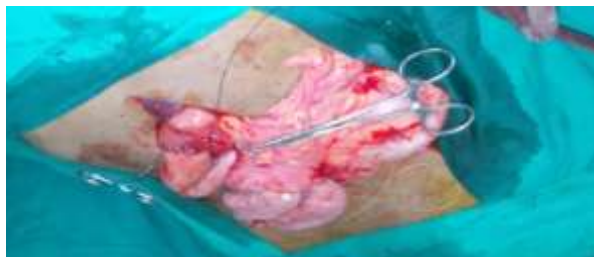

FIG 2 – Operative photograph showing enormously dilated second part of duodenum anastomosed to retrocolic Roux-en-Y jejuna limb.

### III. Discussion

The compression of the anterior duodenal wall by the superior mesenteric artery (SMA) is an uncommon but well recognized clinical entity. SMA syndrome is characterized by compression of third part of duodenum against the aorta by the SMA, resulting in chronic, intermittent, or acute complete or partial duodenal obstruction<sup>1,2</sup>. The vascular compression of the duodenum received many name over the year such as superior mesenteric artery (SMA) syndrome, arterio-mesenteric duodenal compression syndrome, the cast syndrome and chronic duodenal ileus<sup>3</sup>. The reported prevalence in the general population varies between 0.013% and 0.78%<sup>4</sup>. The length and the attachment of the ligament of treitz, the level at which the duodenum crosses the vertebral column and the level of origin of the SMA from the aorta influences the angle of origin of the aforementioned artery<sup>4,5</sup>. The normal SMA- aorta angle of origin ranges between 20°-70° whereas in wilkie's syndrome it is very steep ranging from 6° to 15°<sup>5,6</sup>. In our case there was compression of mid transverse duodenum in the narrowed space between SMA and aorta as aorto mesenteric angle was 12 degrees and aorta mesenteric distance was 3mm.

The main symptoms of wilkie's syndrome are epigastric discomfort and pain followed by vomiting which as the disease progresses become more severe, frequent and causing fluid and electrolyte disturbances with weight loss<sup>7</sup>. Delay in the diagnosis of SMA syndrome can result in malnutrition, dehydration, electrolyte abnormalities, and even death<sup>8</sup>. Our patient was also having similar chronic symptoms for six months but presented to us with acute exacerbation of these symptoms.

The diagnosis of SMA syndrome is confirmed by radiological imaging<sup>9</sup>. The barium meal will show obstruction of the third part of the duodenum with proximal dilation of the organ and a clear cut line which demarks the obliteration of the duodenal lumen by external compression of the SMA.

Upper GI endoscopy may be necessary to exclude mechanical causes of duodenal obstruction but sometimes extrinsic compression of the SMA can be visualized.

Contrast enhanced C T scan is useful in the diagnosis of SMA syndrome and can provide diagnostic information, including aorta-SMA distances and duodenal distension. Also it can be used to assess intra abdominal and retroperitoneal fat<sup>8</sup>. C T was diagnostic in our patient as it revealed the narrow aorto-mesenteric angle and compression of third part of duodenum.

Conservative initial treatment is recommended in all patients with SMA syndrome; this includes adequate nutrition, nasogastric decompression and parenteral fluid administration. Enteral feeding using a double lumen naso-jejunal tube passed distal to the obstruction under fluoroscopic assistance is an effective adjunct in treatment of patients with rapid severe weight loss and also eliminates the need for intravenous fluids and the risks associated with total parenteral nutrition<sup>8</sup>.

Medical treatment may be successful in patients with a short history, moderate symptoms and incomplete duodenal obstruction. It is possible that in patients who are not yet suffering acutely from vascular compression, a high calorie diet which produces weight gain might alleviate or even remove the symptoms<sup>3</sup>. Surgical treatment is indicated when conservative measures are ineffective, particularly in patients with a long history of progressive weight loss, pronounced duodenal dilatation with stasis.

The operative options include duodenojejunostomy, section of the ligament of Treitz and relocation of the duodenojejunal junction (operation of strong), gastrojejunostomy, duodenal anterior replacement<sup>10</sup>. Duodenojejunostomy has become the most frequent treatment with success rate of 90%<sup>10</sup>. The operation of strong is mostly indicated in infants but with a high failure rate. gastrojejunostomy presents the risk of peptic stromal ulceration. All these operative modalities can be laparoscopically approached also. SMA syndrome is an uncommon entity with no specific symptoms and diagnosis depends on a high index of suspicion. Duodenojejunostomy is the choiced surgical procedure with good outcome.

### References

- [1]. Lippel F, Hannig C, Weiss W, Allescher HD, Classen M, Kurjak M. Superior mesenteric artery syndrome: diagnosis and treatment from the gastroenterologist's view. *J Gastroenterol* 2002;37 : 640-3.
- [2]. Gustafsson L, Falk A, Lukes PJ, Gamklou R. Diagnosis and treatment of superior mesenteric artery syndrome. *Br J Surg* 1984; 71 : 499-501.
- [3]. Lorentziadis M L. Wilke's syndrome : A rare cause of duodenal obstruction. *Annals of Gastroenterology* 2011; 24(1): 59-61
- [4]. Welsch T, Buchler MN, Kienle P. Recalling superior mesenteric artery syndrome. *Dig Surg* 2007;24:149-156
- [5]. Kalouche I, Leturgie C, Tronc F, et al. Le syndrome de la pince mesenterique. Apropos d'une observation et revue de la literature. *Ann Chirurg* 1991;45:605-612
- [6]. Shetty AK, Schmidt-Sommerfeld E, Haymon ML. Radiological case of the month. Superior mesenteric artery syndrome. *Arch Pediatr Adolesc Med.* 1999 Mar. 153(3):303-4.
- [8]. Akin J, Gray S, Skandalakis J. Vascular compression of the duodenum: presentation of 10 cases and review of the literature. *Surgery* 1976;79:512-515.
- [9]. Archana Roy, et al. Superior Mesenteric Artery(Wilkie's) Syndrome as a Result of Cardiac Cachexia; *Gen Intern Med* 2005; 20(10) : C3-C4.
- [10]. Kohen E, Amitai M, Apter S, et al. CT Angiography of superior mesenteric artery syndrome. *Am J Roentology* 1998; 171:1279-1281.
- [11]. Ha CD, Alvear DT, Leber DC. Duodenal derotation as an effective treatment of superior mesenteric artery syndrome: a thirty three year experience. *Am Surg* 2008; 74:644-653.